

# The Utilization of Laser-welded Titanium Technology: A Clinical and Laboratory Report for the Edentulous Patient

Brian J Jackson

DDS, Private Practitioners, Utica, New York, USA

**Correspondence:** Brian J Jackson, DDS, Private Practitioners, 2534 Genesee Street, Utica, NY 13502, USA  
e-mail: bjddsimplant@aol.com

## Abstract

Laser-welded technology has become a viable alternative to the conventional lost wax-casting technique in the field of implant dentistry. Studies have demonstrated the predictable nature of laser welded titanium frameworks for endosseous implants in the partial and totally edentulous patient. A standardized impression and fabrication procedure is required for an accurate and predictable superstructure. More long-term studies are needed for more widespread acceptance and usage by dental practitioners.

**Keywords:** Laser-welded titanium, superstructure, direct (open) impression.

## INTRODUCTION

The field of implant dentistry has used bar superstructures to hold retentive features for removable implant-supported overdentures for many years.<sup>1-3</sup> These superstructures offer additional support and retention for the oral prosthesis by means of clips, balls, and their unique design. Laser-welded technology in implant dentistry is not new, but improvements in lasers and technical expertise have made it a predictable alternative to cast-metal technology.<sup>4,5</sup> offer many advantages for its use in bar superstructures, including corrosion resistance, biocompatibility, light weight, and cost. The greatest technical advantage is that thermal expansion and contraction is limited because of the precision of laser energy, thereby allowing a passive fit of the superstructure.<sup>6,7</sup> Laser energy produces little to no heat, thereby avoiding the pitfalls of thermal expansion and distortion of the casting process. The weakest link for bar superstructures for alloy varieties is in the incorporation of soldering in dentistry. Solder joints are prone to corrosive processes and separation, leading to failure of the dental prosthesis. The yield strengths of laser-welded connections are approximately 2½ times stronger than soldered connections. Finally, the cost of fabricating a laser welded titanium bar or repairing a nonpassive connection is easy and more affordable than its conventional gold-alloy counterpart. Laser-welded titanium superstructure bars for the retention of removable-implant overdentures are composed of premachined titanium cylinders screwed into

conventional transmucosal abutments and bars of titanium cut in various lengths. The same technology can be used to incorporate specific attachments to the superstructure to gain additional retention for the final prosthesis. The female housings with inserts are processed in the acrylic of the final prosthesis. In previous years, scientific evidence was established concerning the precision of framework fit of titanium superstructures.<sup>8-10</sup> The studies concluded that no significant difference in marginal fit of titanium frameworks vs cast-alloy frameworks was apparent when viewed radiographically, clinically, or by a photogrammetric technique. However, fewer loose screws were reported 3 weeks postplacement in the titanium framework group, suggesting that the titanium framework group may have a more passive fit. It is well proven that loose screws are associated with higher fracture rates of component parts, additional appointments, eventual implant loss, and case failure. In addition, a more passive superstructure results in a reduced need for soldering, welding, or refabricating a titanium or cast alloy frameworks. Bergendal and Palmquist<sup>11,12</sup> reported that titanium frameworks compared favorably with cast-alloy frameworks. They stated that no statistical significance was found in implant loss, framework fractures, component fit, or margin bone loss. However, complications that were present with the titanium groups included gingival hyperplasia and fracture of resin prosthetic teeth. The edentulous maxilla demonstrated a higher rate of implant loss compared with the mandible in well-



documented findings in the literature.<sup>13-15</sup> A 5-year study by Örtorp et al<sup>16</sup> showed that laser-welded titanium frameworks supported by implants in the edentulous mandible demonstrated results similar to those of cast-alloy frameworks.<sup>16</sup> There was no difference in bone loss, implant failure, or implant component parts. However, if a fracture did occur in the titanium framework group, it was at the distal cantilever junction. In addition, the authors suggested that additional relines or fabrication of a new opposing removable prosthesis may be needed. The study concluded that the choice of material for the framework did not significantly affect the clinical outcome of implant treatment in the edentulous mandible or maxilla.

## METHODS

### Clinical Stage

The prosthetic stage begins 6 weeks after second-stage uncover surgery. Removal of the titanium healing collars and measurements of the gingival sulcus are performed to

allow for the selection of transmucosal abutments. These abutments are placed, and after a confirming radiograph the retaining screws are torqued down as suggested by the specific implant manufacturer's recommendation (Fig. 1). The premachined nonhexed titanium cylinders are screwed into the abutments, and cotton pellets are placed into the long access-screw holes (Fig. 2). The titanium premachined cylinders will become part of the final bar superstructure. A custom tray is fabricated for an open (direct) technique, and a polyvinyl siloxane impression is taken (Fig. 3). The titanium cylinders are secured within the impression tray and sent to the laboratory for the fabrication of a master model (Fig. 4). The healing caps are placed onto the titanium abutments with a hex tool.

### Laboratory Stage

The implant-abutment analogue is screwed into the titanium cylinders found within the impression material, followed by the fabrication of a master cast. The technician selects

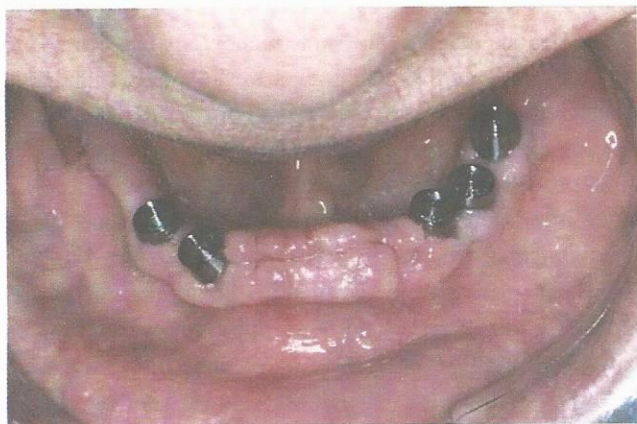

Fig. 1: Intraoperative view after placement of titanium manufacturer's abutments

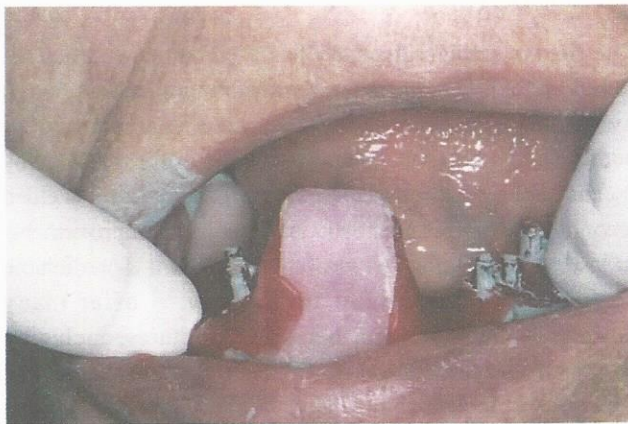

Fig. 3: Custom tray (open)

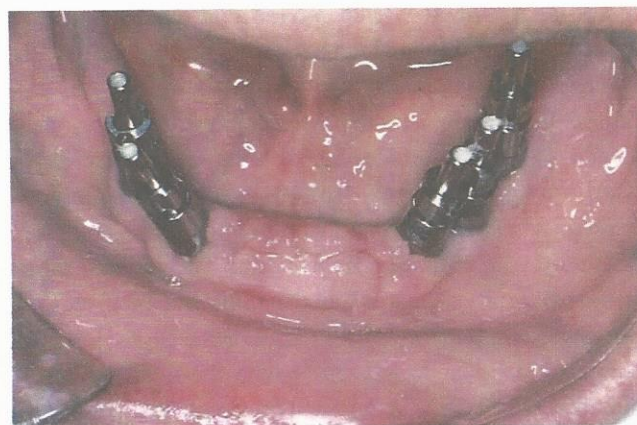


Fig. 2: Occlusal view after insertion of titanium transfer coping with long fixation screws (cotton placed into screw holes)

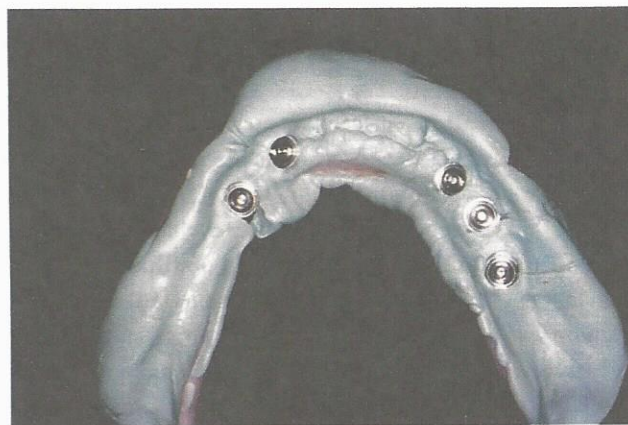

Fig. 4: Internal view of titanium transfer copings fixated in polyvinyl siloxane impression



premeasured titanium bars and uses an alpha laser to spot weld them to the titanium cylinders. The alpha laser can predictably spot weld titanium joints to a maximum depth of 4 mm. The long impression screws of the titanium cylinders are reduced in height and are polished. The technician incorporates a retentive clip into the trial base, and a bite rim is fabricated for the dentist to establish a maxillary/mandibular relationship. After confirmation of passivity of the laser-welded bar intraorally, the laboratory will complete the process of attachment placement, denture tooth set-up, and processing.

### CLINICAL STAGE

The titanium healing caps are removed from the transmucosal abutments and replaced with the titanium laser-welded bar (Fig. 5). A panoramic radiograph is taken with 1 screw placed in a distal implant position. The passivity of the bar is confirmed, and a maxillary-mandibular relationship

is taken (Fig. 6). If the laser-welded bar is not passive, the bar is sectioned and luted together with resin or duralay. The laboratory technician will drill out the nonpassive implant from the master model, repour it in stone, and laser weld the new corrected orientation. A denture tooth try-in confirms vertical dimension, occlusion, esthetics, and phonetics. The final prosthetic visit includes placement of the titanium bar and the processed overdenture with its retentive housings, O-rings, and clips (Figs 7 to 9).

### Case 1

A 68-year-old woman presented for prosthetic treatment of the mandible. Her 2 remaining teeth had a poor prognosis, and a definitive treatment plan was established (Fig. 10). A removable implant-retained overdenture (RP-5) supported by 3 endosseous implants and a complete denture was to be performed.<sup>17</sup> The prosthetic stage was initiated 3 months postsurgery with the attachment of transmucosal abutments

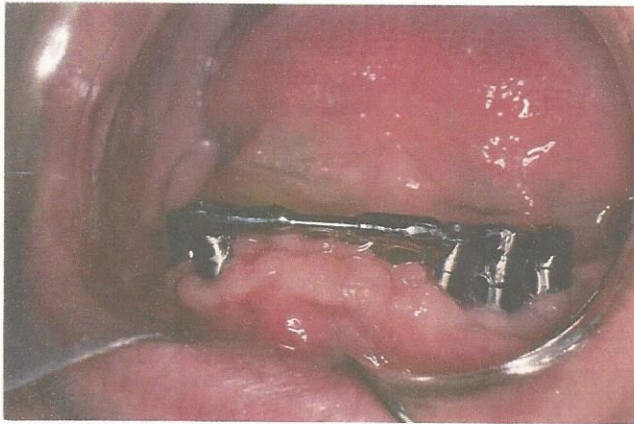


Fig. 5: Laser-welded titanium superstructure bar without attachments

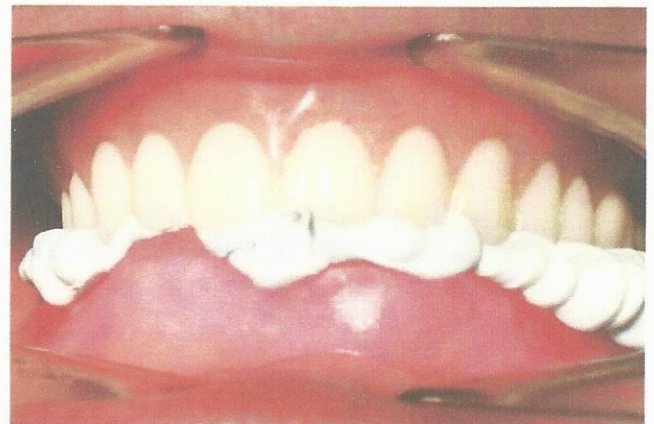

Fig. 6: Frontal view of maxillary/mandibular relationship

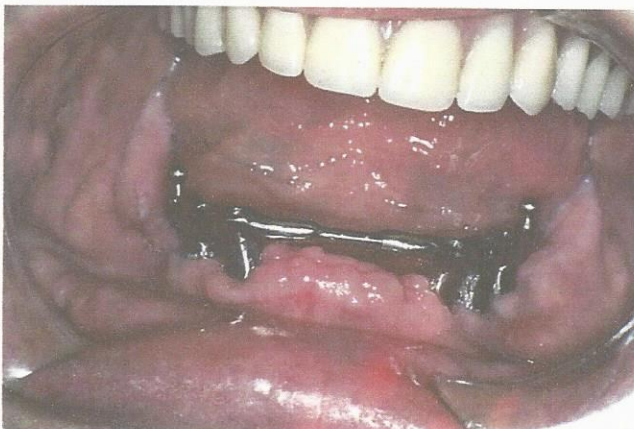

Fig. 7: Frontal view of final laser-welded titanium with distal ball attachments

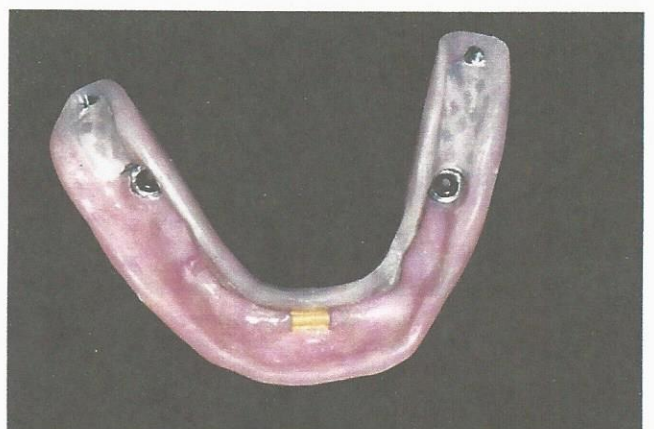


Fig. 8: Tissue side of the mandibular implant-supported overdenture with O-rings and Hader clip



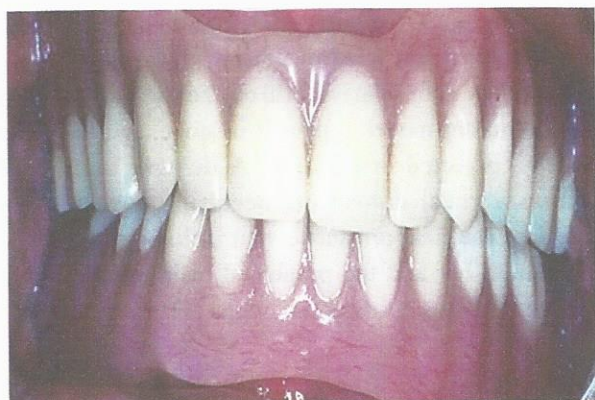

Fig. 9: Frontal view of the final complete maxillary denture and mandibular implant-supported overdenture (centric relation)

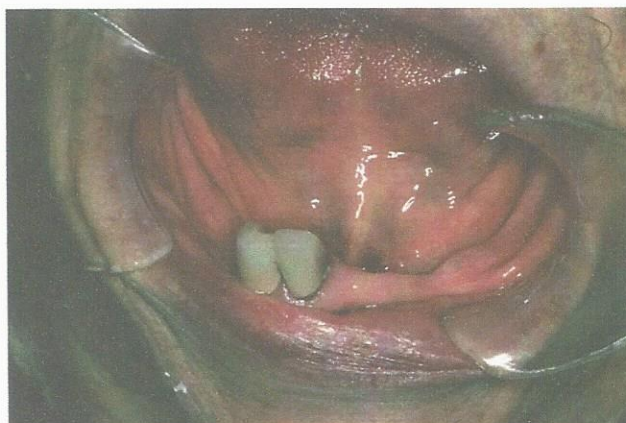

Fig. 10: Preoperative view of mandibular arch

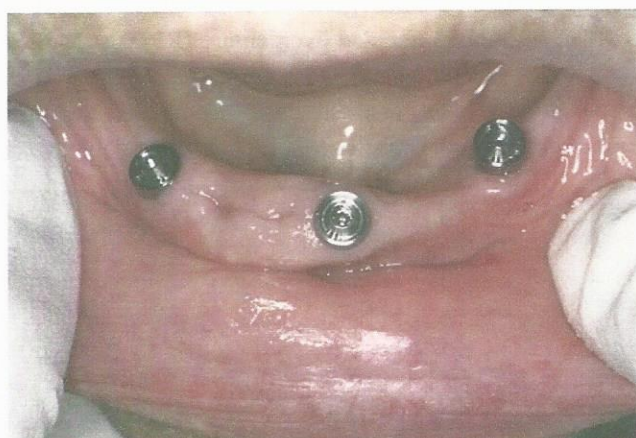

Fig. 11: Occlusal view of titanium abutments torqued into 3 endosseous implants

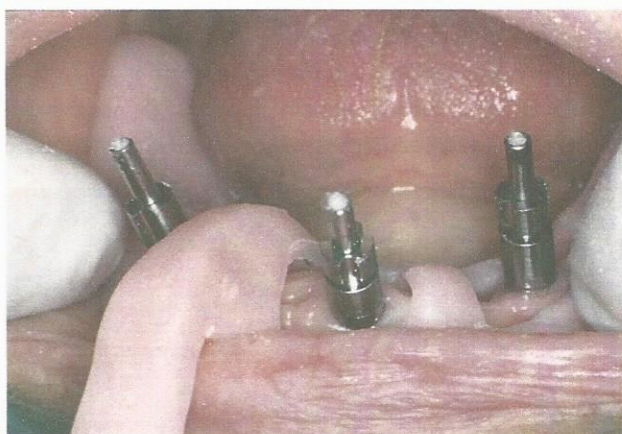


Fig. 12: Occlusal view of transfer copings with block-out cotton and open custom tray

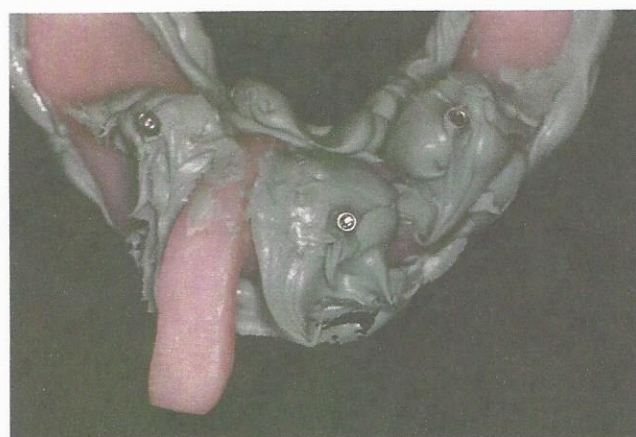

Fig. 13: Custom tray, polyvinyl siloxane impression material, and penetrating titanium transfer copings

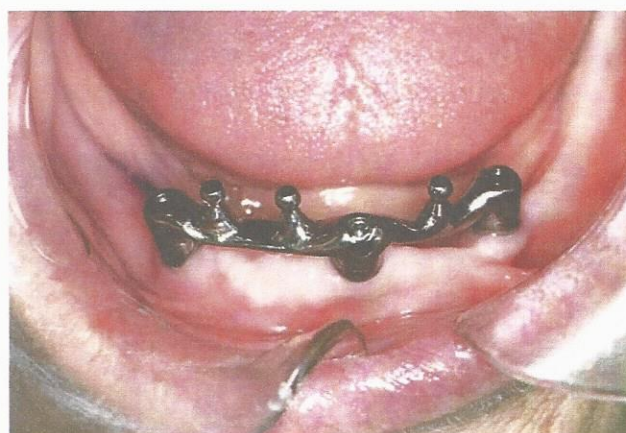

Fig. 14: Occlusal view of final laser-welded titanium bar with 3 ball attachments

(Fig. 11). A custom tray (open) with polyvinyl siloxane impression material was used to capture the pre-machined titanium cylinders screwed to the abutments (Figs 12 and 13).

A bar try-in, maxillary-mandibular registration, and denture tooth setup were performed (Fig. 14). This was followed by final placement of the mandibular prosthesis (Figs 15 to 17).



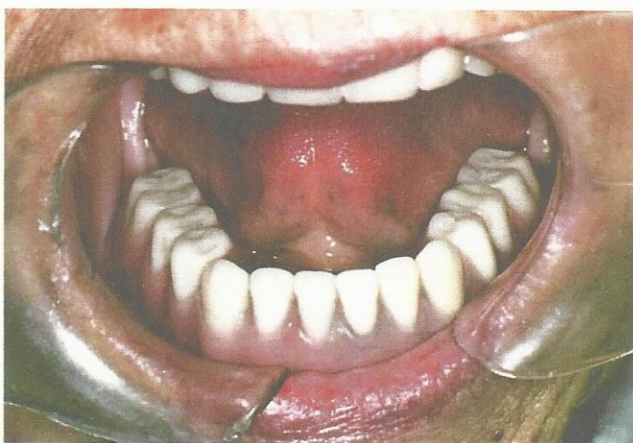

Fig. 15: Occlusal view of mandibular implant-supported overdenture

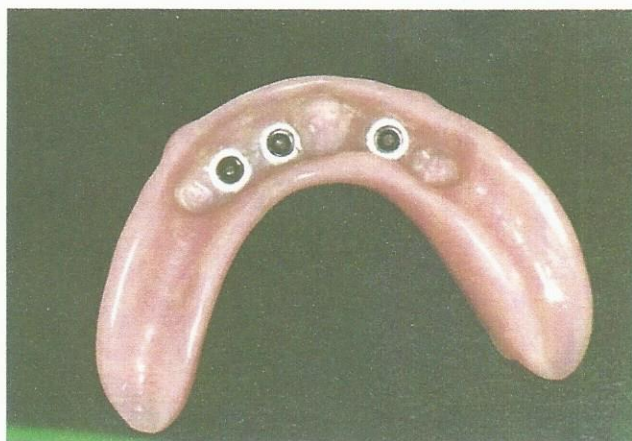


Fig. 16: Tissue side of mandibular overdenture with 3 O-rings

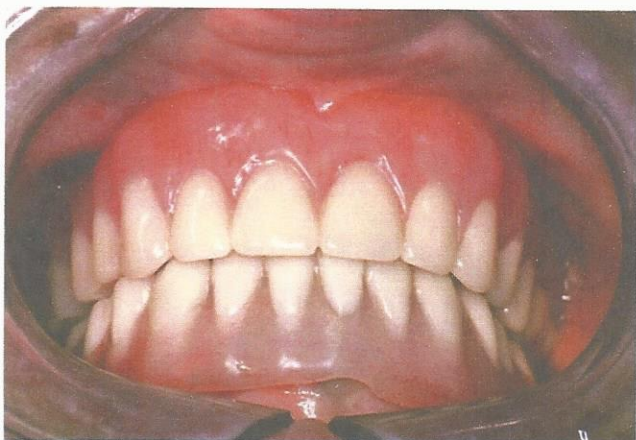

Fig. 17: Frontal view of final maxillary denture and mandibular implant overdenture (centric relation)

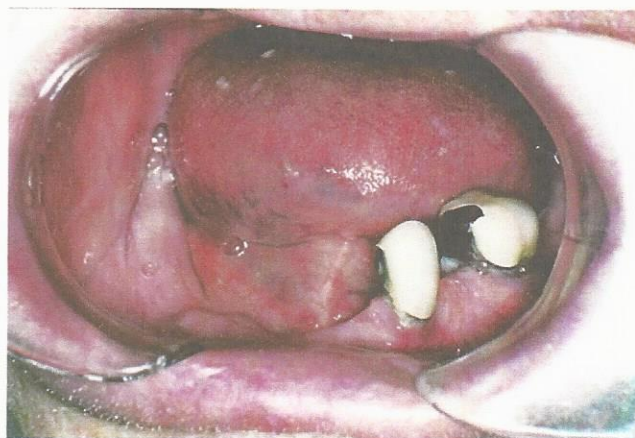

Fig. 18: Intraoperative view of mandibular arch (presurgical)

## Case 2

A 65-year-old man presented to the office with a concern about 2 remaining mandibular teeth (Fig. 18). A treatment plan was established to include a mandibular implant-supported overdenture (RP-4) and a complete maxillary denture.<sup>18</sup> His prosthetic stage was initiated 3 months post extraction and implant placement. The impression stage included the placement of titanium transmucosal abutments, the placement of premachined nonhexed titanium cylinders, and the utilization of an open custom tray (Fig. 19). The next appointment confirmed the passivity of the titanium laser welded bar and the establishment of a maxillary-mandibular relationship (Fig. 20). A final bar and attachments were placed, followed by the definitive prosthesis (Figs 21 to 23).

## Case 3

A 60-year-old woman presented to the office with a chief complaint of "I hate the way my teeth look, and they seem to be moving" (Fig. 24). A diagnosis of chronic apical periodontitis was made, and a treatment plan of 6 endosseous implants and a removable maxillary implant overdenture (RP-5) was established.<sup>19</sup> A polyvinyl siloxane impression was taken with a custom tray of the premachined nonhexed titanium cylinders screwed into the titanium transmucosal abutments (Figs 25 and 26). A titanium laser-welded bar was tried in, and a maxillary-mandibular relationship was taken (Fig. 27). After a denture tooth set-up was tried in, the final prosthesis was placed and the occlusion was adjusted based on implant protective occlusion principles (Figs 28 and 29).<sup>20,21</sup>



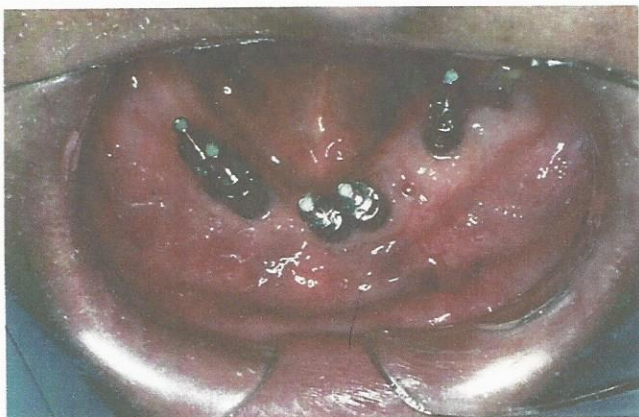

Fig. 19: Occlusal view after insertion of tapered abutments and AOII titanium transfer copings (cotton in long screw posts)

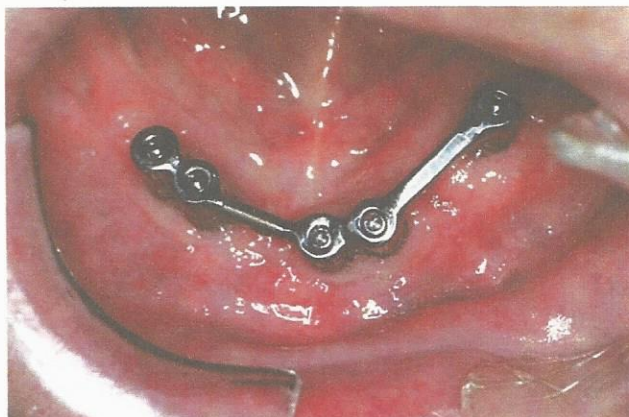


Fig. 20: Laser-welded titanium bar without attachments

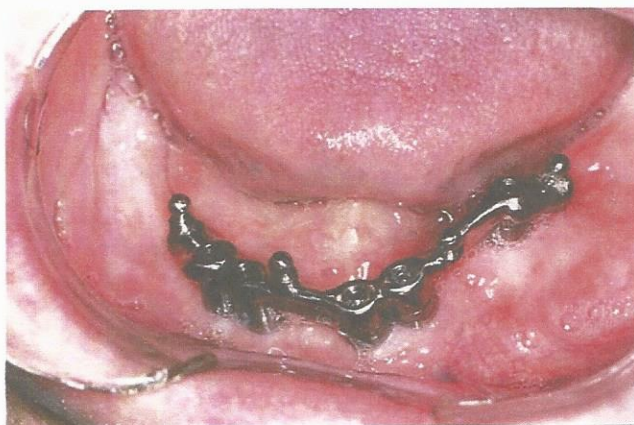

Fig. 21: Complete laser-welded titanium superstructure with 4 ball attachments

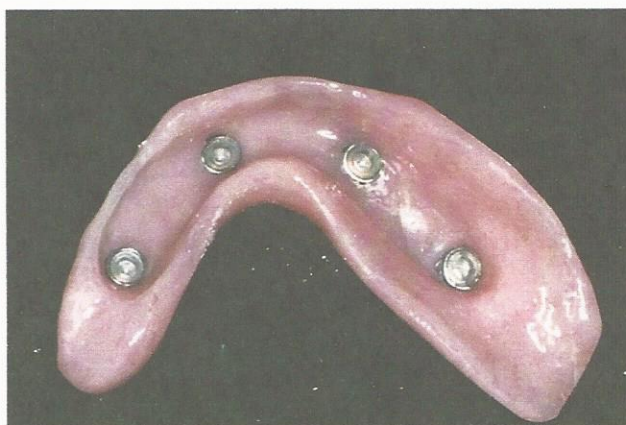


Fig. 22: Tissue side of mandibular overdenture with 4 nylon cap attachments in metal housings

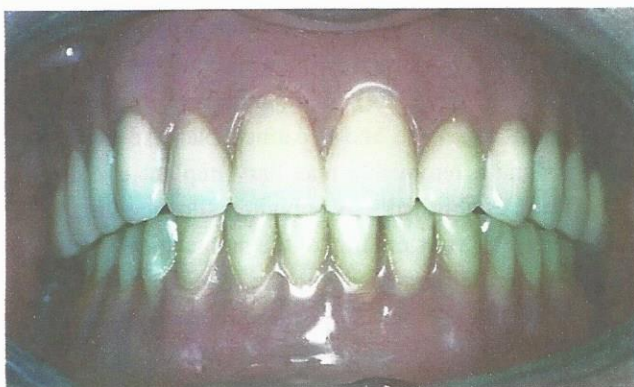

Fig. 23: Frontal view of complete maxillary denture and implant-supported mandibular overdenture

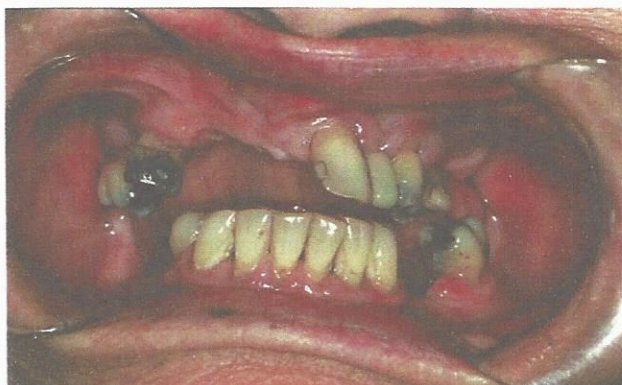
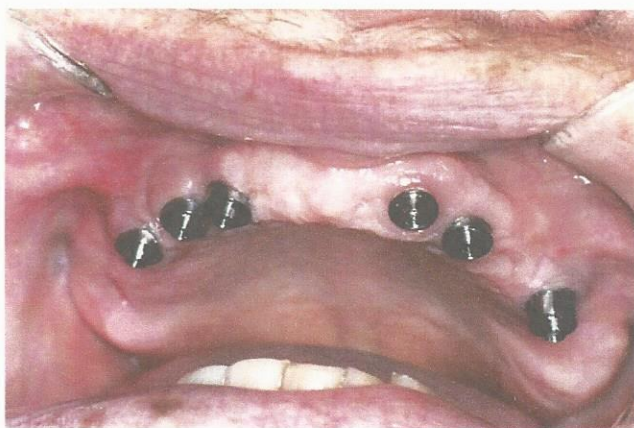
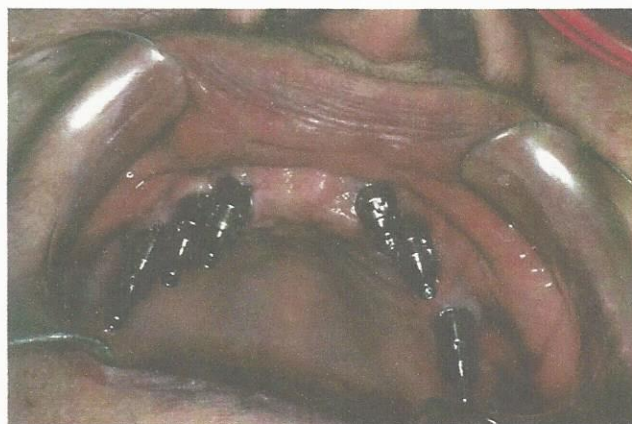Fig. 24: Intraoral view before maxillary extractions and implant-surgery

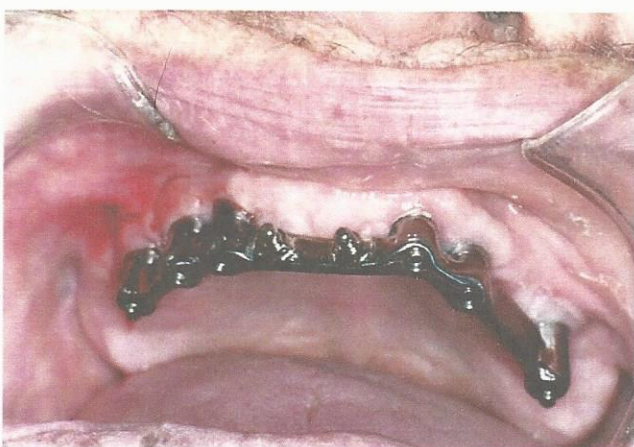



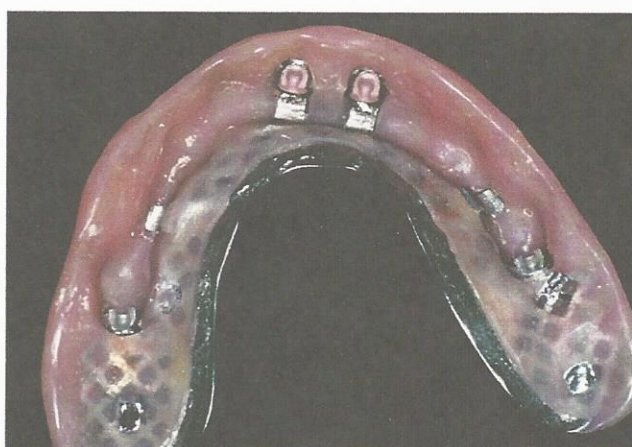**Fig. 25:** Occlusal view of titanium abutments fixated to endosseous implants



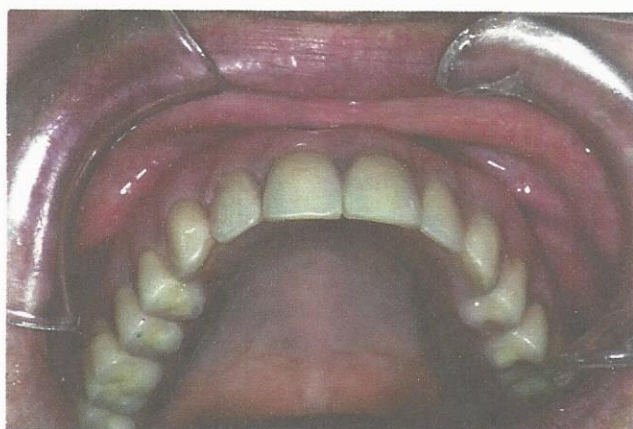
**Fig. 26:** Frontal-occlusal view of AOII titanium transfer coping and long fixation screws with cotton pellets inserted into tapered abutments



**Fig. 27:** Final laser-welded titanium bar with 4 ball attachments



**Fig. 28:** Tissue side of maxillary implant-supported overdenture with 4 strategy attachments



**Fig. 29:** Occlusal view of complete maxillary implant-supported overdenture



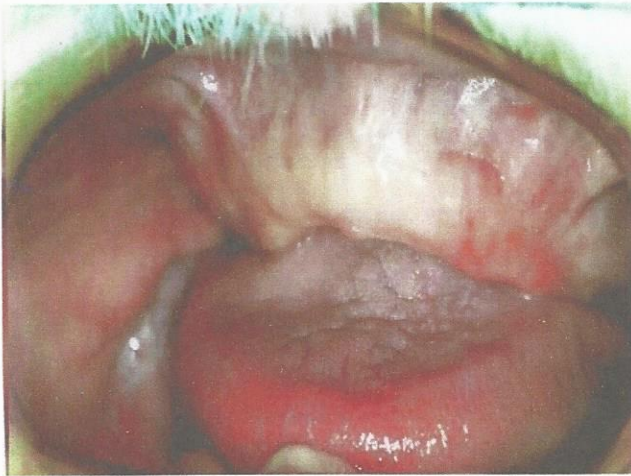

Fig. 30: Preoperative view of maxillary arch

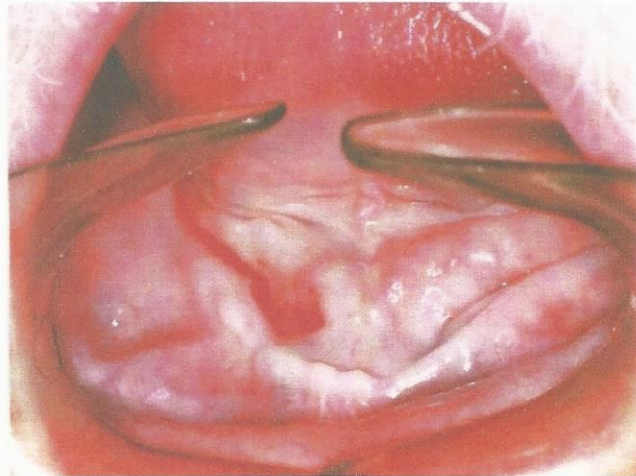


Fig. 31: Preoperative view of mandibular arch

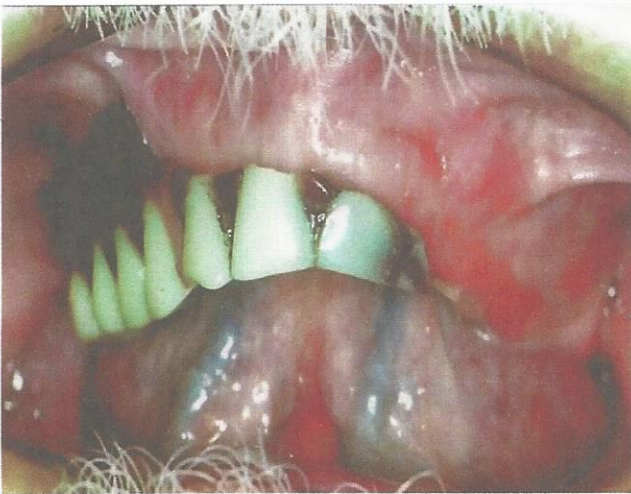

Fig. 32: Existing complete maxillary denture

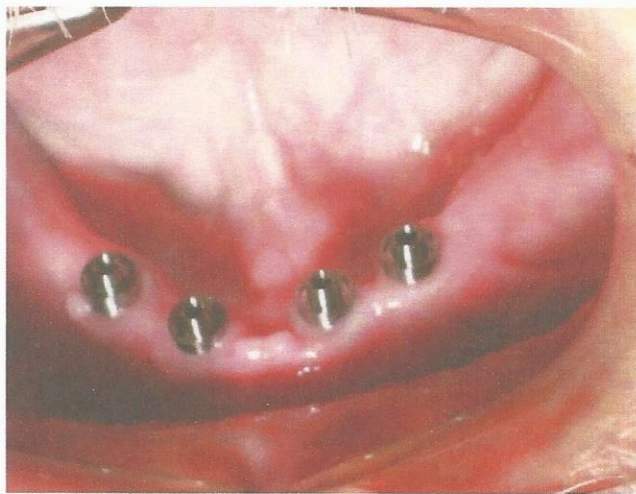


Fig. 33: Occlusal view of titanium abutments fixed to endosseous implants

#### Case 4

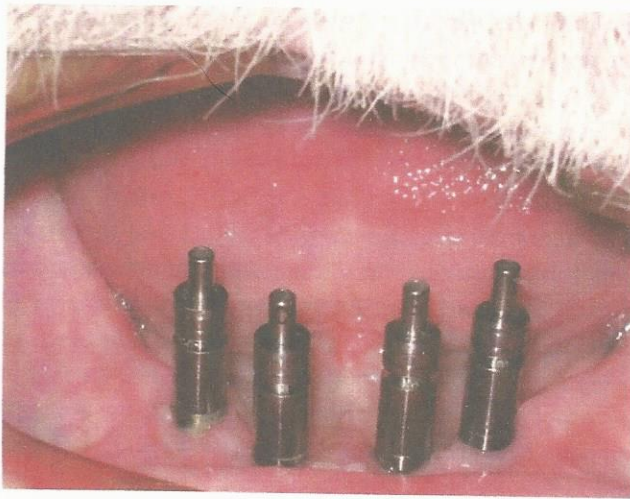
A 62 years old male presented to our office for an evaluation of his oral cavity. The patient's chief complaint was "I really want a smile." The dental history revealed that the maxillary denture was fabricated 30 years ago and the mandibular denture has never been worn (Figs 30 and 31). The existing maxillary complete denture was fractured, extremely worn, discolored and lacked stability and retention (Fig. 32). The treatment plan accepted by the patient was a complete maxillary denture and a mandibular 4-implant retained removable overdenture. The prosthetic stage was initiated with the placement of four transmucosal abutments, and 4 premachined titanium transfer copings fixed to each other by 15 mm long screws (Figs 33 and 34). A polyvinyl siloxane

impression was taken with a custom tray to capture the position and angulation of the implants (Fig. 35). One locator was welded to the middle position of the bar to assist with establishing a correct maxillary/mandibular relationship (Fig. 36). A titanium laser-welded bar superstructure was fabricated and tried into confirm passivity (Fig. 37). The final prosthetic appointment included placement of the final superstructure containing 3 locator attachments and the processed mandibular overdenture (Figs 38 and 39).

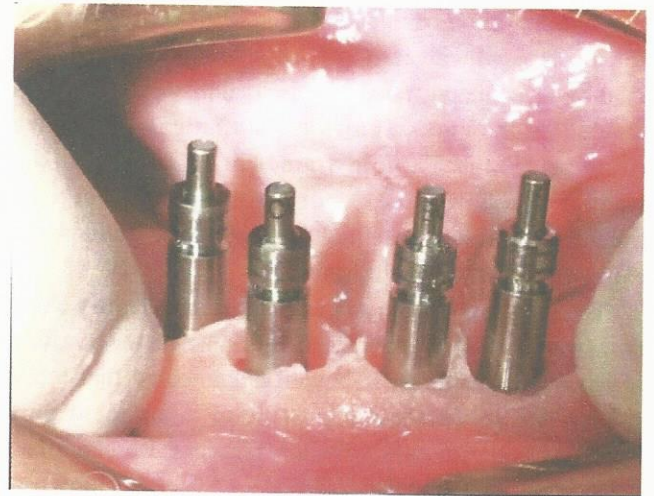
#### DISCUSSION

A critical issue in long-term success of endosseous implants is the ability to reduce stress to the crestal bone.<sup>22</sup> Research has demonstrated that laser-welded technology shows no

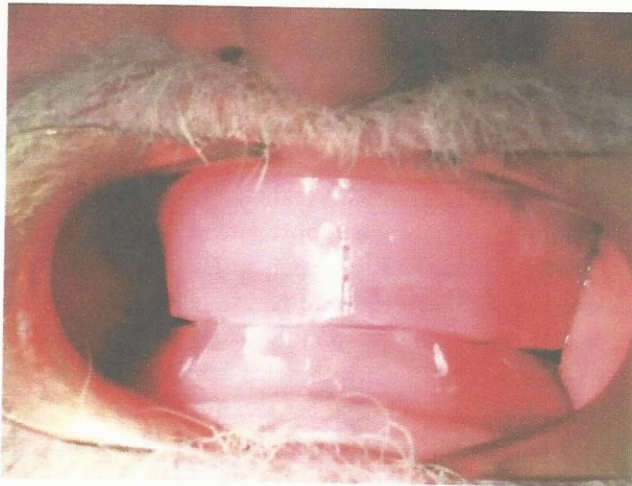




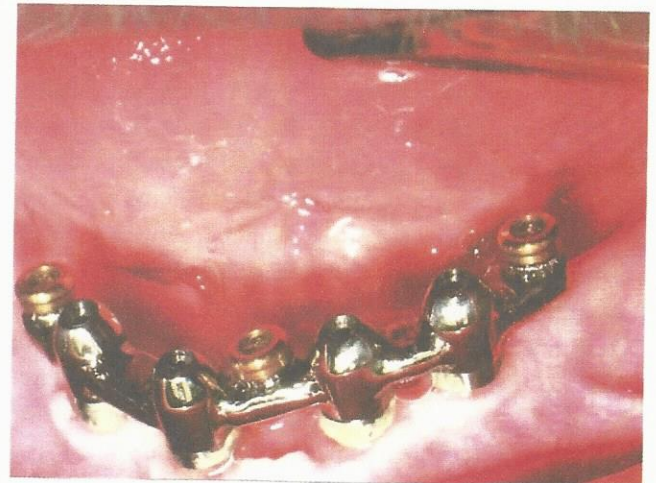**Fig. 34:** Frontal view of titanium transfer copings and long fixation screws inserted into tapered abutments



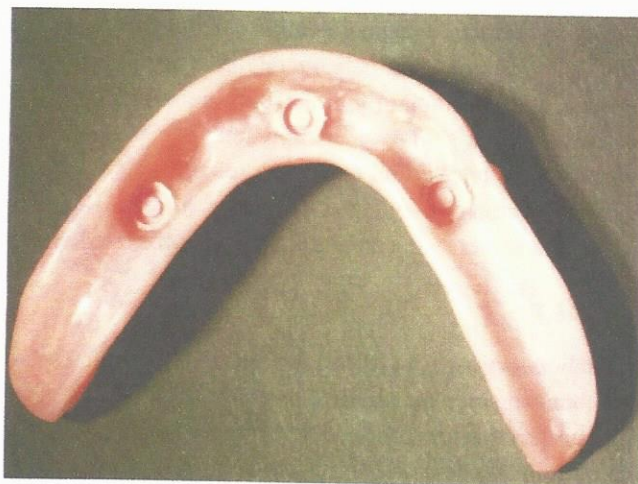**Fig. 35:** Titanium transfer copings-tapered abutments and custom tray



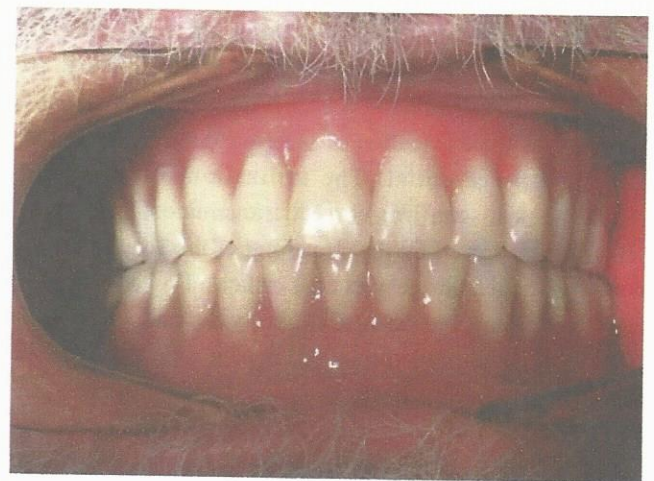
**Fig. 36:** Frontal view of maxillary-mandibular relationship



**Fig. 37:** Laser-welded titanium superstructure bar with locator attachments



**Fig. 38:** Underside of mandibular overdenture



**Fig. 39:** Frontal view of the final complete maxillary denture and mandibular implant supported overdenture (centric relation)



significant difference in superstructure fit or implant loss when compared with conventional gold-alloy frameworks. Studies have demonstrated that thermal distortion of laser-welded frameworks shows no statistical difference compared with cast-gold frameworks. However, the standard deviation in distortion is greater for cast frameworks, so the potential of nonpassive frameworks exists on a more frequent basis.

The lack of loose screws associated with laser-welded frameworks at follow-up clinical visits indicates the passivity of bar superstructures. It is well-documented that loose screws are precursors to prosthetic component part fractures, bone loss, and implant failure.<sup>23</sup> Research has successfully exhibited that laser-welded superstructures can be used in the edentulous maxilla and mandible. The complication rate, including bone loss, superstructure fracture, and implant loss, statistically parallels cast gold-alloy superstructures. As a result, it is recommended that additional implants be placed in areas of poor bone quality and that strict attention be paid to implant occlusal principles. The cases presented in this study were treatment planned with bone quality as a significant factor. The incorporation of additional implants and bar superstructures without cantilevers was designed into the maxillary case.<sup>24,25</sup> Research has indicated that some complications of laser welded titanium frameworks exist, with the most common being prosthetic veneer fracture from the superstructure. In recent years, the development of low fusing porcelains and improved technical expertise has demonstrated that sufficient bond strength can be achieved. However, this complication is moot in the application of laser-welded technology in removable implant-supported bar overdentures. Most other reported complications, such as gingival hyperplasia, implant loss, and superstructure fracture, are not unique to titanium frameworks. A disciplined, predictable approach to the fabrication of laser-welded titanium superstructures is essential. The utilization of panoramic radiographs to confirm correct transmucosal abutment placement followed by the stretching of the fixation screw with a calibrated torque wrench is critical. The laser-welded titanium bar must be evaluated clinically and radiographically with 1 screw tightened into a distal implant site. The retentive features must be placed within the confines of interocclusal clearance and based on angulation of force. The correct maxillary/mandibular relationship should be established and confirmed with a try-in of the denture tooth set-up. After confirmation of vertical dimension, occlusion, and esthetics,

the complete implant overdenture can be processed with the appropriate retentive housings and attachments. The cases included in this study have demonstrated the utilization of laser-welded bar technology for the edentulous maxilla and mandible. In case 3, an implant and soft tissue-supported removable overdenture (RP-5) with 6 implants was demonstrated. Because of poor bone quality, a removable prosthesis was selected with additional implants placed, without cantilevers, and with low-profile attachments incorporated into the bar. The advantage of using a removable prosthesis is the ability for removal in instances of nocturnal bruxism. In case 2, an implant-supported removable over denture (RP-4) with 4 O-ring and nylon attachments was performed. The prosthesis was completely implant supported with distal cantilevers placed 1.5 x at the A-P spread, 0° posterior teeth, and a lingualized bilateral balanced occlusion.<sup>26</sup> Case 3 exhibited a soft tissue and implant supported removable overdenture (RP-5). The treatment plan included 3 endosseous implants placed in good bone quality and a titanium superstructure without cantilevers and with 3 O-ring retentive attachments. This prosthesis is excellent when retention is the major objective to treatment, whereas support and stability are less paramount. A marked reduction in tissue ulceration is accomplished with this type of removable prosthesis.

The final case presented in this study incorporated the utilization of locator attachments laser-welded to the superstructure as the prosthesis' retentive feature.<sup>27,28</sup> The locator attachment contain dual retention, and is durable due to its pivoting nature within the metal housing. In addition, it is an ideal attachment for limited interocclusal space due to its low profile (2.5 mm) design. Finally, the locator system has various retentive strengths to allow the dentist to customize the patients retentive needs as related to bone quality, implant numbers and hand strength. For example, in this study we incorporated 1-5 lb and 2-3 lb locators for a total initial quantitative retention of 11 lb. As the bone matures, the dentist can select different locators with various increasing strengths to maximize retention.

## CAVAET

The laboratory aspect of the superstructure fabrication stage has changed since the publication of the initial article. The titanium premachined cylinders now contain grooves for retention rather than the fluting as seen in earlier designs. The change was made simply due to the economics of manufacturing the fluting aspect of the titanium cylinders.



The previous design required a separate machine to mill-in the fluting which took additional time and expense. The new design containing grooves is accomplished by the same machine that is used in all aspects of the fabrication of the titanium cylinders. The clinical significance of the change demonstrates no detrimental effects on the accuracy of the impression transfer stage.

Although the incorporation of the locator attachment system has introduced many advantages to the retentive aspect of the prosthesis, a limitation of food entrapment has been illustrated in this case report. Food debris can accumulate into the female component of the locator attachment and then condensed into a solid rigid mass, preventing the complete seating of the prosthesis. In addition, the male component and housing of the system located within the overdenture may distort when excessive pressure is required to seat the prosthesis. It can be difficult for the patient to thoroughly cleanse the attachment unless thorough attention to detail is followed. It is essential that the patient be instructed on how to thoroughly clean the attachments (i.e. rubber tips, toothpicks) to prevent food entrapment within the locator attachments. This limitation does not out way the many advantages of this highly innovative attachment system.

## CONCLUSION

Laser-welded titanium technology in the field of implant dentistry has evolved to a stage of predictable results. Studies have proven that minimal complications are associated with this technology when compared with conventional cast-alloy frameworks. The use of bar superstructures with titanium bars can be successful in maxillary and mandibular edentulous arches. These cases demonstrate that a long-term good prognosis can be achieved when organized treatment plans are used. Although laser-welded titanium frameworks have improved significantly over recent years, long-term studies are required before widespread acceptance and use by dental practitioners. However, the current body of research on this subject is certainly promising.

## ACKNOWLEDGMENTS

The author wishes to thank his assistants, Melanie Fink, Anita Elwell and Tatyana Lyubezhnina, for their assistance in the preparation of this article, and Paul Giovannone, CDT, (Biogenic Dental Laboratories, Utica, NY) for his dental technical expertise.

## REFERENCES

1. English CE. Bar patterns in implant prosthodontics. *Implant Dent* 1994;3:217-29.
2. Bidez MW, Chen Y, McLoughlin SW, et al. Finite element analysis of fourabutment Hader bar designs. *Implant Dent* 1993;2:171-76.
3. Dolder E. The bar joint mandibular denture. *J Prosthet Dent* 1961;11:686-707.
4. Sjögren G, Andersson M, Bergman M. Laser welding of titanium in dentistry. *Acta Odontol Scand* 1988;46:247-53.
5. Walter M. Titanium in restorative dentistry. *Proceedings of the 4th International Symposium on Titanium in Dentistry*. Geneva, Switzerland; 1998:75. Available at: <http://www.bioconnect.com/esympo/istd4/walter.html>. Accessed January 2002.
6. Jemt T. Three-dimensional distortion of gold alloy castings and welded titanium frameworks. Measurements of the precision fit between completed implant prostheses and the master casts in routine edentulous situations. *J Oral Rehabil* 1995;22:557-64.
7. Jemt T, Linde'n B. Fixed implant supported prostheses with welded titanium frameworks. *Int J Periodont Restor Dent* 1992;12:177-84.
8. Jemt T, Lie A. Accuracy of implant-supported prostheses in the edentulous jaw: Analysis of precision of fit between cast gold-alloy frameworks and master casts by means of a three dimensional photogrammetric technique. *Clin Oral Implants Res* 1995;6:172-80.
9. Rubenstein JE. Stereo laser-welded titanium implant frameworks. Clinical and laboratory procedures with a summary of 1-year clinical trials. *J Prosthet Dent* 1995;74:284-93.
10. Jemt T, Henry P, Linde'n B, Naert I, Weber H, Bergstrom C. A comparison of laser-welded titanium and conventional cast frameworks supported by implant in the partially edentulous jaw: A 3-year prospective multicenter study. *Int J Prosthodont*. 2000;13:282-88.
11. Bergendal B, Palmquist S. Laser-welded titanium frameworks for fixed prostheses supported by osseointegrated implants: A 2-year multicenter study report. *Int J Oral Maxillofac Implants*. 1995;10:199-206.
12. Bergendal B, Palmquist S. Laser-welded titanium frameworks for implantsupported fixed prostheses: A 5-year report. *Int J Oral Maxillofac Implants* 1999;14:69-71.
13. Misch CE. Maxillary denture opposing an implant prosthesis. In: Misch CE (Ed). *Contemporary Implant Dentistry* (2nd ed). St Louis, Mo: CV Mosby Co 1999:639-44.
14. Robinson SC. Physiological placement of artificial anterior teeth. *Can Dent J* 1996;35:260-66.
15. Jemt T, Bergendal B, Arvidsson K, et al. Laser-welded titanium frameworks supported by implants in the edentulous maxilla: A 2-year prospective multicenter study. *Int J Prosthodont* 1998;11:551-57.
16. Örtorp A, Linde'n B, Jemt T. Clinical experiences of laser-welded titanium frameworks supported by implants in the edentulous mandible: A 5-year follow-up study. *Int J Prosthodont* 1999;12:65-72.
17. Misch CE. Treatment options for mandibular implant overdenture: An organized approach. In: Misch CE (Ed). *Contemporary Implant Dentistry*. St Louis, Mo: CV Mosby Co;1993:223-40.



18. Judy KWM, Richter R. Implant supported overdenture prosthesis. *Pract Periodont Aesthet Dent* 1991;3:51-56.
19. Kapur KK. Occlusal patterns and tooth arrangements. In: Lang Br, Kelsey CC (Eds). *International Prosthodontics Workshop on Complete Denture Occlusion*. Ann Arbor, Mich: University of Michigan 1973;1-50.
20. Payne SH. A posterior set up to meet individual requirements. *Dent Digest* 1941;47:20-22.
21. Pound E, Murrell GA. An introduction to denture simplification, phase I. *J Prosthet Dent* 1973;29:570.
22. Misch CE. Occlusal considerations for implant-supported prostheses. In: Misch CE (Ed). *Contemporary Implant Dentistry*. St Louis, Mo: CV Mosby Co 1993;705-33.
23. Biron P, Sutter F, Beaty K, et al. The role of screws in implant systems. *Int J Oral Maxillofac Implants* 1994;9:48-63.
24. Jemt T. Implant treatment in resorbed edentulous upper jaws: A three year follow-up on 70 patients. *Clin Oral Implants Res* 1993;4:187-94.
25. Smedberg JI, Lothigius E, Bodin I, et al. A clinical and radiological two years follow-up study of maxillary overdentures on osseointegrated implants. *Clin Oral Implants Res* 1993;4:39-46.
26. English C. The critical A-P spread. *Implant Soc J* 1990;1:2-3.
27. Vogel RC. Implant overdentures: A new standard of care for edentulous patients-current concepts and techniques. *Functional Esthetics and Restorative Dentistry* 2007;1(2):30-36.
28. Karabuda C, Yaltirik M, Bayraktar M. A clinical comparison of prosthetic complications of implant-supported overdentures with different attachment systems. *Implant Dent* 2008;17:74-81.



**Brian J Jackson**  
(bjddsimplant@aol.com)