TWO PEER-REVIEWED CE CREDITS
Plaque Inhibition
Richard Demke, DDS, pg. 96

PRODUCT FOCUS
Oral Cancer
Detection/Prevention, pg. 114

17TH ANNUAL MIDWINTER SHOWCASE
100+ Products Highlighted, pg. 70

BUYERS' GUIDE
Air-Driven Handpieces, pg. 162

DENTISTRY TODAY®

DENTISTRYTODAY.COM

30 Years of Clinical Excellence 30th Anniversary 1982 2012

VOLUME 31 NO. 2 • THE NATION'S LEADING CLINICAL NEWS MAGAZINE FOR DENTISTS • FEBRUARY 2012

ENDODONTICS



Dennis G. Brave, DDS
Bioceramics, Part 2
pg. 118

RESTORATIVE



David Clark, DDS
Treating Black Triangle Cases
pg. 134

IMPLANTS

Brian J. Jackson, DDS
Effective Denture Stabilization
pg. 130

LOOKING TO THE FUTURE

pg. 102

DR. GORDON J. CHRISTENSEN

**********FIRM**CAR-RT LOT**C-008
9328
GLENN KARWOSKI
KARWOSKI & COURAGE
STE 2600
60 S 6TH ST
MINNEAPOLIS MN 55402-4431
P243
13877
1

Place this peel-off label on FREEInfo card on page 1.

Effective Denture Stabilization in an Atrophic Mandible

Brian J. Jackson, DDS

Denture stabilization with implants can make a dramatic difference in the lives of patients, providing benefits in function, aesthetics, and overall health. However, for many denture wearers, traditional implant treatment may be unattainable for any number of reasons. A primary factor is frequently the expense of the procedure. Inadequate bone can be a challenge for many patients, requiring extensive bone grafting prior to conventional implant placement. Finally, as patients age, many simply do not wish to devote a great deal of time to a surgical process that can go on for months and requires a considerable amount of recovery time.

As a general practitioner who has an extensive history placing conventional dental implants, I am an enthusiastic advocate for the traditional procedure. However, I have seen many patients in my practice for whom it is impractical or simply out of reach financially. The last few years have seen a trend developing for a different kind of implant treatment that may provide an excellent solution for some denture patients involving mini-dental implants (MDIs) (also known as small-diameter implants).

MDIs were initially introduced as transitional devices to retain a denture while a conventional implant was allowed to osseointegrate. What many practitioners found was that if a patient did not return to have these transitional implants removed within 3 to 6 months, they became very difficult to remove, as they too had integrated into the bone.[1] In 2004, the FDA-approved MDI System (3M ESPE) (formerly IMTEC Sendax MDI implants) for long-term use.

In recent years, this treatment has been increasingly discussed by the implantology community, primarily as a solution for patients who are not ideal candidates for conventional implants or who cannot afford this option. In my practice, it has been particularly appropriate for patients with atrophic mandibles who do not wish to go through the expense or time of conventional implant treatment with significant bone grafting.

The official protocol for placing MDIs is taught to general practitioners as well as specialists in one-day seminars, making it a relatively simple technique to learn. A minimum of 4 implants are recommended for mandibular denture stabilization. The sites for each implant are marked on the patient's tissue, and a 1.1-mm pilot drill is used to create entry points. The mini-implants are inserted into the pilot holes and then advanced with a progression of a finger driver, winged thumb wrench, and a ratchet. As a clinician with significant experience in implant placement, I use a more advanced procedure utilizing a flap in cases if appropriate, but a basic case can typically be performed without this step. After placement of the implants, the patient's denture is then fitted with housings that snap onto the o-ring heads of the implants. This allows the denture to be tissue supported but implant retained, which offers the capability of immediate loading.

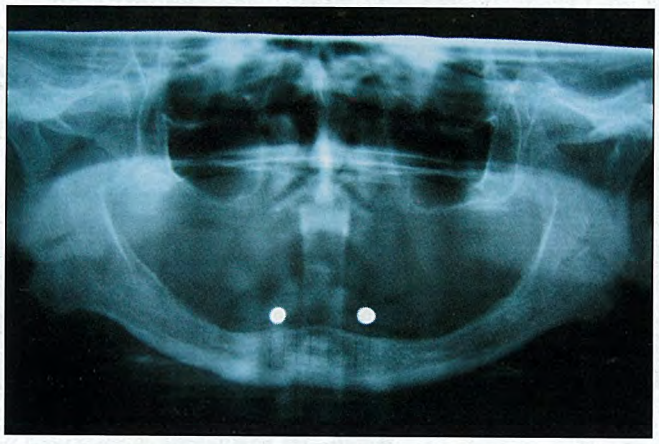

Figure 1. Initial panoramic radiograph.

Reported success rates for MDIs have ranged from 91% to 97.4%.[2-5] The most comprehensive study tracked 2,500 implants and reported a 5-year survival rate of 94.2%.[4] As the body of research for this treatment grows larger, additional evidence can be expected to support the suitability of MDIs in the edentulous mandible.

The following case report demonstrates a typical implant procedure, highlighting the difference it can make in a patient's life and confidence.

CASE REPORT

Diagnosis and Treatment Planning

A 55-year-old female presented to the office stating that "my bottom teeth fall out." The patient's maxilla had been edentulous for 8 years, and the mandible for 5 years. She wore a full upper denture and a mandibular denture and stated that she was in the habit of applying and reapplying denture adhesive 8 to 10 times per day.

While the patient's primary concern was the lack of stability in the mandible, she also had a minor concern with sores from the dentures. The patient found her condition very mentally debilitating, as she was a relatively young and healthy woman. She stated that she felt that her mouth looked like an 80-year-old's, and she didn't have confidence speaking or smiling because of the lack of stability of her lower denture.

Significant items revealed by her medical history were: the patient was a smoker and she was also being treated for hypertension. Panoramic (Figure 1) and cephalometric radiographs were taken, as well as pretreatment photos. The diagnosis established was an atrophic mandible, after which diagnostic models were made of the existing dentures, and edentulous impressions were taken of the upper and lower arches.

The patient returned for a consultation appointment to discuss the available treatment options. A number of choices were presented and discussed with regard to time, expense, and complications. One treatment option was the creation of a new complete set of maxillary and mandibular dentures. For additional stability, 4 MDIs could be placed in the mandible to stabilize the lower denture. Alternatively, bone grafting could be performed and conventional implants placed in the mandible.

After discussing the options, the patient elected to move forward with MDI treatment. The steps of the treatment were discussed in

continued on page 132

Effective Denture Stabilization...
continued from page 130

greater detail and the patient was also informed of the risks of implant treatment prior to signing a consent form.

Treatment Begins: Surgical Appointment

At the surgical appointment, anesthesia was administered via bilateral blocks with 2% lidocaine (1:100,000 epinephrine). A surgical guide was placed and osteotomy sites were indicated through the template by inserting an endodontic explorer through the soft tissue to create bleeding points. A No. 2 round bur was utilized to penetrate the soft tissue down to the crest of bone (Figure 2). A conservative mucoperiosteal flap was created with a 15C Bard Parker blade and reflected to expose the crest (Figure 3). A 1.1-mm drill was then utilized to create four 5-mm osteotomies, into which the 1.8 mm by 10 mm collared o-ball MDIs were placed. Prior to implant placement, four 1.1-mm drills ligated with dental floss were placed into the osteotomies to evaluate parallelism (Figure 4). The implants were advanced into the bone by using a finger driver and thumb wrench. The area was then secured with 4-0 vicryl sutures. The underside of the patient's transitional mandibular denture was relined with COE-SOFT reline material (GC America) and then relieved to accommodate the heads of the implants, and the patient was dismissed.

Figure 2. Tissue punches marked the sites for the implants.

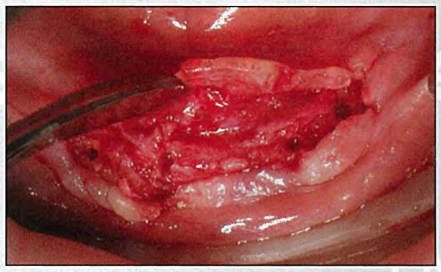

Figure 3. Mucoperiosteal flap with 4 osteotomies.

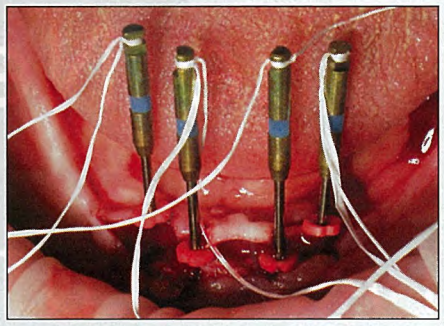

Figure 4. Four (1.1 mm) drills were used to gauge parallelism.

Figure 5. The collared o-ball mini dental implants (MDIs) following 2 weeks of healing time.

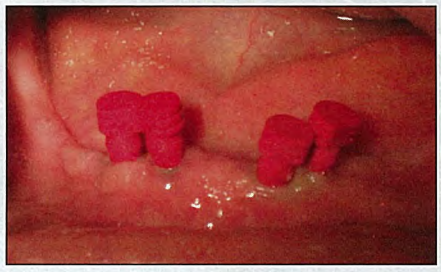

Figure 6. MDIs impression caps.

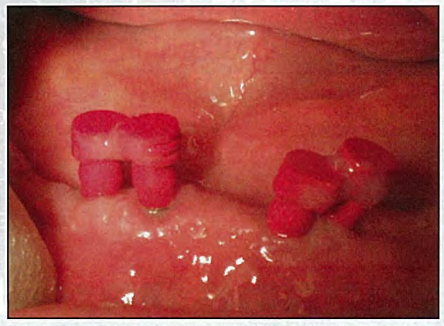

Figure 7. MDIs impression caps were luted with light-cured flowable resin (Heliomolar [Ivoclar Vivadent]).

Figure 8. The maxillary denture and mandibular implant overdenture setup (in wax) (Blueline Teeth [Ivoclar Vivadent]).

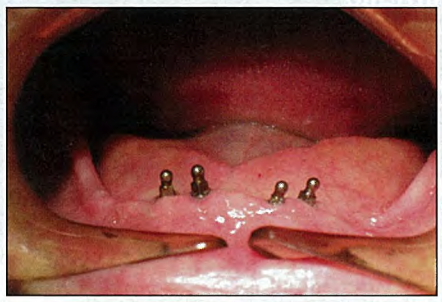

Figure 9. The implants, 4 weeks postsurgical.

Figure 10. Mandibular overdenture with housings for the o-rings in the undersurface.

Postsurgical Impression and Prosthetic Appointments

Two weeks later, the patient returned for suture removal and for impressions (Figure 5). MDIs impression copings were placed on the o-ball implants and luted together with light-cured flowable resin (Heliomolar [Ivoclar Vivadent]) (Figures 6 and 7), and impressions were captured with a vinyl polysiloxane impression material (Imprint 3 [3M ESPE]) Secondary impressions were also taken for fabrication of the maxillary complete denture.

Two weeks following the impression appointment, a maxillary-mandibular relationship was taken with a unibase (wax rim), and a shade and mold were selected. A denture try-in with the teeth (Blueline Teeth [Ivoclar Vivadent]) set up in wax (Figure 8) was completed one week following this appointment. One week later, the final maxillary and mandibular prostheses were delivered (Figures 9 to 12).

Postdelivery Appointments

Follow-up appointments have shown the patient to be thrilled with the treatment. She stated that it had made a huge change in her life and had given her much more confidence. After experiencing the level of stability made possible with the MDIs in the mandible, the patient is now considering a similar procedure for the maxilla. Despite the fact that stability in the maxilla was not an initial concern for the patient, she now feels that if it can be made better, she would like to pursue treatment to improve her confidence even more.

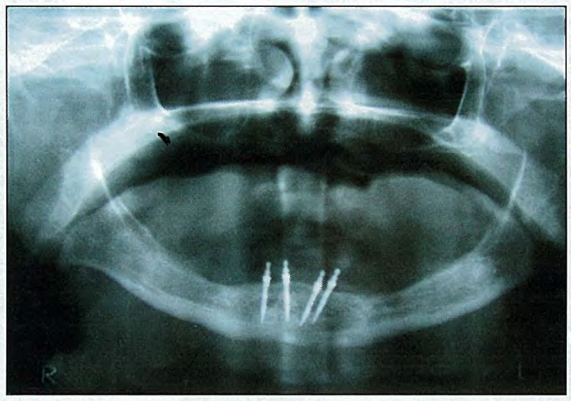

Figure 11. Final panoramic radiograph.

Figure 12. Completed dentures in centric occlusion.

DISCUSSION

This case demonstrates 2 variances from the standard protocol for MDI placement, in that a flap was performed and the implants were not immediately loaded. As a dentist who has been traditionally trained in implant placement, I personally prefer to create flaps in cases with atrophic mandibles. While not strictly required for MDI placement, a flap allows the clinician greater certainty of placement in the middle of the crest. In cases where more bone is available, a flapless procedure is quite straightforward.

Because the patient in this case was relatively young, the decision was made to not immediately load the implants in order to allow the bone and soft tissue to mature more fully. This simply provides more assurance that the implant will survive in the long-term with a young patient in robust health. Immediate loading is often very suitable for older patients, due to the fact that their occlusal forces may not be as strong, and they are seeking an immediate quality of life improvement rather than an implant that will survive for 10 years or more. However, in this case it was determined to allow for a longer period of bone maturation prior to engaging the retentive feature of the overdenture. Fixation of the implant at placement is an essential requirement for success of the MDI system, as well as with conventional endosseous implants.

It is critical that the clinician utilize an array of different clinical findings and

technology to assist with long-term treatment decisions. Most recently, I have incorporated the usage of the Periotest (Medizintechnik Gulden). While not required in the MDI protocol, I am using it in addition to a torque wrench to establish another quantitative value prior to immediate load cases, as it provides additional information. It is also a test that can be performed throughout the life of the implant, which helps me follow implant specific integration over time. Most importantly, however, is that the implant after placement demonstrates zero mobility visually upon percussion.

In this case report, a moderate divergence of the left implants is exhibited in the final panoramic radiograph. This clinical result occurred despite parallel 1.1-mm drills placed in the osteotomies prior to implant placement. This clinical finding can occur due to several reasons, including the partial osteotomy protocol, self-tapping nature of the implant, quality of bone, and the clinician's surgical decision making. The partial osteotomy surgical protocol combined with the self-tapping nature of the implant and soft bone can allow for minor variations in the implant path. It is essential for the novice or experienced clinician to guide the placement of the implant in the path desired for an ideal outcome. The presence of anatomical structures such as the mental foramen and a potential anterior loop of the inferior alveolar nerve may dictate implant placement. Therefore, it is very common to see a distal implant divergence, due to the clinician's tendency to position the implant mesial to the neurovascular complex. Finally, divergence of implants is successfully managed by the versatility of the MDI system's MH-1 o-ring housing design. This prosthetic attachment design allows for a firm retentive feature within a 30° implant divergence. The patient has been seen on a 4-month recall basis for the past 2 years, demonstrating excellent retention, minimal o-ring wear and excellent crestal bone levels. Most importantly, the patient feels that the implant-retained overdenture is a huge success.

CONCLUSION

Many dentists have likely seen denture patients who have suffered great losses in their quality of life, and have been making do with temporary measures like adhesives and over-the-counter relines for far too long. MDIs give dentists an important tool to reach this pool of patients and provide them with an affordable and less invasive path to denture stabilization. As the patient in this case demonstrates, added stability can bring back the quality of life to a large population of patients.✦

References

1. Balkin BE, Steflik DE, Naval F. Mini-dental implant insertion with the auto-advance technique for ongoing applications. *J Oral Implantol*. 2001;27:32-37.
2. Bulard RA, Vance JB. Multi-clinic evaluation using mini-dental implants for long-term denture stabilization: a preliminary biometric evaluation. *Compend Contin Educ Dent*. 2005;26:892-897.
3. Griffitts TM, Collins CP, Collins PC. Mini dental implants: an adjunct for retention, stability, and comfort for the edentulous patient. *Oral Surg Oral Med Oral Pathol Oral Radiol Endod*. 2005;100:e81-e84.
4. Shatkin TE, Shatkin S, Oppenheimer BD, et al. Mini dental implants for long-term fixed and removable prosthetics: a retrospective analysis of 2514 implants placed over a five-year period. *Compend Contin Educ Dent*. 2007;28:92-99.
5. Christensen GJ. Critical appraisal. Mini implants: good or bad for long-term service? *J Esthet Restor Dent*. 2008;20:343-348.

Dr. Jackson graduated from Utica College *cum laude* with a BS degree in biology. He received his DDS degree at State Univeristy of NY at Buffalo, School of Dental Medicine. Dr. Jackson completed postgraduate training at St. Luke's Memorial Hospital Center's general practice residency program and completed his formal oral implantology training at New York University, School of Dentistry. Dr. Jackson is a Diplomate of the American Board of Oral Implantology/Implant Dentistry, a Fellow of the American Academy of Implant Dentistry (AAID), and a member of the ADA. Currently, he serves as Trustee for the AAID, and is past president of the Northeast District of the AAID, as well as, past president of the Oneida-Herkimer County Dental Society. Dr. Jackson is an attending staff dentist for Faxton-St. Luke's Healthcare general practice residency program. He has also joined the faculty of the Las Vegas Maxicourse in Oral Implantology. He has presented oral implantology lectures Internationally and has published peer reviewed articles in various journals on the topic of implant dentistry. Dr. Jackson is treasurer for the AAID's Research Foundation and a scientific reviewer for the *Journal of Oral Implantology*. He can be reached via e-mail at bjjddsimplant@aol.com.

Disclosure: Dr. Jackson receives finaicial compensation from 3M ESPE for lecturing on MDI Implants.

FREEinfo, circle 83 on card